

CASE REPORTS

9. Moore KL: *The Neck: Clinically Oriented Anatomy*, 2nd edition. Baltimore, Williams & Wilkins, 1985, pp 983-1068

10. Nathan MD, Leshner RT, Keller PA Jr: Intractable hiccups (singultus). *Laryngoscope* 1980; 90:1612-8

11. Davis JN: An experimental study of hiccups. *Brain* 1970; 93:851-72

12. Eisele JH, Noble MIM, Katz J, Fung DL, Hickey RF: Bilateral phrenic-nerve block in man. Technical problems and respiratory effects. *ANESTHESIOLOGY* 1972; 37:64-9

13. McCredie M, Lovejoy FW Jr, Kaltreider NL: Pulmonary function in diaphragmatic paralysis. *Thorax* 1962; 17:213-7

14. Benzon HT, Prasad YS, Barthwell DA: The value of fluoroscopy before performing a phrenic nerve block. *ANESTHESIOLOGY* 1981; 55:469-70

15. Sarnoff SJ, Sarnoff LC: Prolonged peripheral nerve block by means of indwelling plastic catheter. Treatment of hiccup (Note on the electrical localization of peripheral nerve). *ANESTHESIOLOGY* 1951; 12:270-5

16. Kepes ER, Andrews C, Baruch H, Hupert C, Radnay PA, Shibutani K: Electrical stimulation of phrenic nerve in treatment of hiccups. *NY State J Med* 1972; 72:2769-70

Anesthesiology

1998; 88:527-9

© 1998 American Society of Anesthesiologists, Inc.

Lippincott-Raven Publishers

General Anesthesia in a Patient with an Enlarged Saber Sheath Trachea

Eda J. Wallace, M.B.B.S., F.F.A.R.C.S.I.,* Frances Chung, M.D., F.R.C.P.C.†

"SABER SHEATH" refers to a trachea that is widened in the anteroposterior diameter and markedly narrowed in the transverse plane. This abnormality may give the appearance of a mediastinal mass on lateral radiograph. Saber sheath tracheas are usually smaller than the normal trachea and are associated with chronic obstructive pulmonary disease. We present the case of a patient with a trachea that conformed to the parameters of a saber sheath but was much larger than a normal trachea. This resulted in our inability to mechanically ventilate this patient because of excessive leakage around the endotracheal cuff.

Case Report

A 34-yr-old man, with a 14-yr history of ankylosing spondylitis, presented for an arthroplasty of the right hip. His cervical, thoracic,

* Neuroanaesthesia Fellow.

† Deputy Anaesthetist in Chief.

Received from the Department of Anaesthesia, Toronto Western Division, Toronto Hospital, University of Toronto, Toronto, Ontario, Canada. Submitted for publication July 28, 1997. Accepted for publication October 6, 1997.

Address reprint requests to Dr. Wallace: Department of Anaesthesia, Toronto Western Division, Toronto Hospital, 399 Bathurst Street, Toronto, Ontario, Canada, M5T 2S8. Address electronic mail to: edawallace@compuserve.com

Key words: Anesthesia; ankylosing spondylitis; laryngeal mask, saber sheath trachea.

and lumbar spines were fused. We opted for an awake fiberoptic intubation with a size 8.0 Mallinckrodt endotracheal tube. This was performed uneventfully; the mass spectrometer indicated a satisfactory end-tidal CO₂ tracing, and his O₂ saturation remained at 99%, with good air entry bilaterally over the thorax as he was manually ventilated. Anesthesia was then induced with a sleep dose of propofol, and he was paralyzed with vecuronium, 6 mg. Anesthesia was maintained with O₂/nitrous oxide and isoflurane (1%). Within 1 min, it was noted that a large leak was present around the endotracheal tube, which was associated with inadequate ventilation of the patient with the North American Drager 2 set at a tidal volume of 800 ml and a frequency of 10 breaths/min. The cuff had been inflated progressively with up to 10 ml of air, and the end-tidal CO₂ ranged from 50 to 60 mmHg. Suspecting a torn cuff, we decided to change to another size 8.0 endotracheal tube using a Sheridan Tracheal Tube Exchanger (Sheridan Catheter Corp., Argyle, NY). However, the leakage continued after replacement. After removal, the original endotracheal tube was noted to be without defect. Another tube exchange using a size 8.5 endotracheal tube was attempted unsuccessfully. The patient remained easy to manually ventilate with an oropharyngeal airway only. In view of his immobile neck and the uncertainty about the reason for the leakage, we decided to reverse the muscle relaxants and wake him, with the aim of investigating his upper airway.

Computed tomography of the neck done within 1 h revealed an enlarged trachea. The largest anteroposterior diameter of the trachea measured 43 mm, and the transverse diameter in that plane was 19 mm. The transverse diameter was less than one half the anteroposterior diameter, in keeping with the description of a saber sheath trachea.¹ No mediastinal masses were noted (Fig. 1). This patient had had previous radiologic investigations of the chest and cervical spine, but no comments had been made as to the size or shape of the trachea. The preoperative chest radiograph report noted only that the lungs were clear. The posteroanterior chest view of the trachea

CASE REPORTS

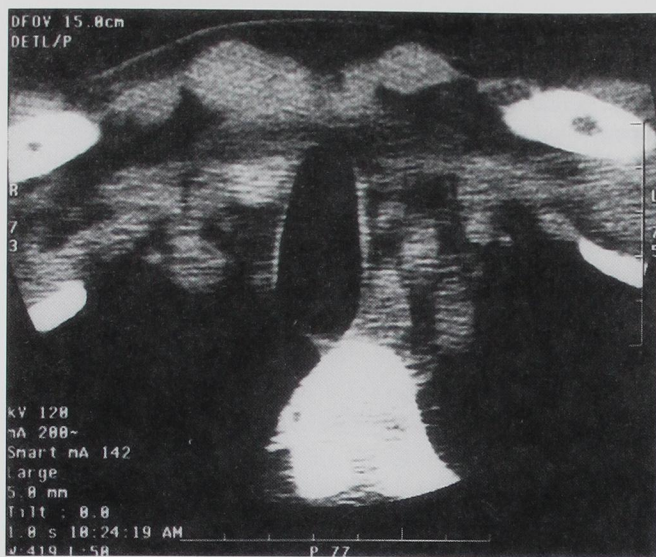


Fig. 1. Cross-sectional view of patient's intrathoracic trachea. Scale 1 cm:1 cm.

was normal because the transverse diameter was only 19 mm. The lateral chest radiograph did not assist in the diagnosis because of underpenetration of the film. The cervical spine radiographs revealed ossification of the posterior longitudinal ligament, bony ankylosing of the lower cervical vertebrae, and marked limitation of movement between flexion and extension views.

The findings were explained to the patient. He had already donated blood and was insistent that we proceed with surgery. Anesthesia was again induced 3 h later with intravenously administered midazolam, 1 mg, fentanyl, 100 μ g, and propofol, 150 mg, and 100% O₂ was provided by manual ventilation. A size 4.0 laryngeal mask was then placed without difficulty, and he was allowed to breathe spontaneously with O₂/nitrous oxide and end-tidal isoflurane (average 2%) using a low flow circle absorber system. The patient was placed in the left lateral position for surgery. Anesthesia was uneventful thereafter.

Discussion

In the normal trachea, the upper limits of the transverse and anteroposterior diameters in men aged 20–79 yr are 25 mm and 27 mm, respectively, using computed tomography views.² The most common tracheal shape is round or oval; other shapes include horseshoe with a flat posterior membrane, inverted pear shape, and square.³ The average male tracheal diameter is 20 mm, with a cross-sectional area of 314 mm².¹ Our patient had an anteroposterior diameter of 43 mm and a transverse diameter of 19 mm. Using the formula of an ellipse, the cross-sectional area of the trachea was calculated to be 641.93 mm², twice the average measurement. The cross-sectional area of the trachea is best

characterized by the ratio of the transverse and anteroposterior diameters, also called the *tracheal index* (TI). Two abnormal cross-sectional shapes occur: discord trachea (TI > 1) and saber sheath trachea (TI \leq 0.6). In this case, TI was calculated as 0.4 (19 mm/43 mm). Saber sheath trachea is closely associated with chronic obstructive pulmonary disease and is seen almost exclusively in men. The deformity affects only the intrathoracic trachea, leading to abrupt widening of the cervical trachea.

During normal expiration, the intrathoracic tracheal dimensions are reduced. This reduction is exaggerated in those with chronic obstructive pulmonary disease. It is believed that in patients with saber sheath trachea, the narrowing in the transverse plane is a result of bending of the cartilaginous rings, and the narrowing in the anteroposterior plane is caused by inward bulging of the posterior membranous wall. However, there is a lack of evidence to prove this theory.¹ It has also been theorized that the development of the saber-shaped trachea is a result of degeneration, vascularization, and ossification of the tracheal rings.¹ One of the possible stimuli is chronic tracheal collapse from excessive coughing.

Saber sheath trachea has not been reported to be associated with ankylosing spondylitis, and chronic obstructive pulmonary disease is not a feature of ankylosing spondylitis.

Abnormalities of the upper airway may not be detected on routine posteroanterior or lateral chest radiographs. For our patient, these were reported as being normal. We cannot advocate doing computed tomography of the neck to detect an enlarged saber sheath trachea in patients with ankylosing spondylitis because there have been no previous cases reported in the literature.

Clinical and radiologic methods designed to assess the ease of intubation would not have helped in discovering this abnormality. No preoperative tests are known to be useful in such cases.

The endotracheal tubes commercially available, when inflated, all assume a circular diameter. Thus, patients with an unusually shaped or enlarged trachea will tend to have a leak unless the cuff approximates the tracheal wall. With a size 8.0 Mallinckrodt endotracheal tube, the approximate diameters across the cuff at various volumes are: no air, 10 mm; 5 ml of air, 20 mm; 10 ml of air, 29 mm. Additional measurements revealed that to occlude the anteroposterior diameter of 43 mm, one would need to inflate the endotracheal tube with approximately 32.5 ml of air. The transverse diameter, however, would be occluded with just 5 ml of air. This would result in relative overinflation of the cuff, which could cause tracheal damage by mucosal ischemia⁴ or rupture of the cuff with subsequent deflation. To

CASE REPORTS

avoid this, one may opt to use the largest endotracheal tube available, inflate the cuff as usual, and then pack the oropharynx with enough gauze to create an airtight seal. This is useful for patients in whom muscle relaxation and mechanical ventilation are needed and for those who may have a full stomach to reduce the risk of aspiration. For patients in whom this risk is not present, a brain laryngeal mask may be satisfactory. Ankylosing spondylitis has been listed as a contraindication to the insertion of a laryngeal mask.⁵ In a case report of a patient with ankylosing spondylitis,⁶ it was reportedly impossible to insert a laryngeal mask because of a severely acute angle between the oral and pharyngeal axes. The neck of our patient had been pathologically fused at an angle greater than 90°, making insertion of the laryngeal mask easy.

In conclusion, we have presented the case of a patient with ankylosing spondylitis who was difficult to mechanically ventilate because of an unusually large trachea and

subsequent leakage from around the cuff. The laryngeal mask was effectively used as an alternative to the endotracheal tube.

References

1. Greene R, Lechner GL: Saber-sheath: A clinical and functional study of marked coronal narrowing of the intrathoracic trachea. *Radiology* 1975; 115:265-8
2. Breathach E, Abbott GC, Fraser RG: Dimensions of the normal trachea. *AJR Am J Roentgenol* 1984; 142:903-6
3. Gamsu G, Webb WR: Computed tomography of the trachea: Normal and abnormal. *AJR Am J Roentgenol* 1982; 139:321-6
4. Cooper JD, Grillo HC: Analysis of problems related to cuffs on intratracheal tubes. *Chest* 1972; 62:218-7
5. Pennant JH, White PF: The laryngeal mask and its uses in anesthesiology. *ANESTHESIOLOGY* 1993; 79:144-63
6. Ishimura H, Minami K, Sata T, Shigematsu A, Kadoya T: Impossible insertion of the laryngeal mask airway and oropharyngeal axes. *ANESTHESIOLOGY* 1995; 83:867-9

Anesthesiology
1998; 88:529-31
© 1998 American Society of Anesthesiologists, Inc.
Lippincott-Raven Publishers

Unusual Hypotension and Bradycardia in a Patient Receiving Fenfluramine, Phentermine, and Fluoxetine

James M. Rich, C.R.N.A., M.A.,* Lucas Njo, M.D.,† Kevin W. Roberts, Pharm. D.,‡ K. Patman Smith, C.R.N.A., M.S.*

FENFLURAMINE§ and phentermine are used for the management of obesity.¹ Phentermine acts *via* central

catecholamine pathways.² Fenfluramine and fluoxetine act *via* serotonergic pathways.^{2,3} Additionally, with chronic use, fenfluramine has been reported to have catecholamine-depleting effects.^{3,4} Reported side effects, in patients taking fenfluramine and phentermine, range in severity from bothersome¹ to fatal.^{5,6} We report a case of a patient receiving a long-term course of fenfluramine, phentermine, and fluoxetine who experienced hypotension and bradycardia during regional anesthesia with sedation.

* Staff Anesthetist, Anesthesiology and Pain Management Service, Department of Veterans Affairs Medical Center, Dallas, Texas.

† Assistant Professor in Anesthesiology at University of Texas Southwestern Medical Center, Anesthesiology and Pain Management Service, Department of Veterans Affairs Medical Center, Dallas, Texas.

‡ ICU Clinical Pharmacy Specialist, Clinical Pharmacy Service, Department of Veterans Affairs Medical Center, Dallas, Texas; Adjunct Clinical Assistant Professor, University of Missouri at Kansas City, Kansas City, Missouri.

Received from the Anesthesiology and Pain Management Service and Clinical Pharmacy Service of the Dallas Department of Veterans Affairs Medical Center, Dallas, Texas. Submitted for publication June 12, 1997. Accepted for publication October 10, 1997.

Address reprint requests to Mr. Rich: 5214 Gulfport Drive, Rowlett, Texas 75088. Address electronic mail to: jrofdallas@aol.com

Key words: Antiobesity drugs; autonomic dysfunction; catecholamine depletion; fenfluramine; fluoxetine; phentermine; regional anesthesia; sedation-analgesia; weight-loss drugs.

§ Voluntarily withdrawn by manufacturer September 1997.

Case Report

A 50-yr-old, 90-kg, 185-cm, American Society of Anesthesiologists' physical status II man presented for PIP fusion of the right second toe. Medical history was positive for a distant episode of hepatitis A and cessation of smoking 20 yr previously. Baseline electrocardiograph (ECG) revealed sinus bradycardia of 56 beat/min. Preoperative laboratory studies were unremarkable. Personal and family history were negative for anesthesia-related complications. Although initially denied, medication history was positive for phentermine, 18.75 mg/day, combined with fenfluramine, 20-40 mg/day for approximately